

Original article:

Drug-induced stevens-johnson syndrome : Experience from a tertiary care hospital

***Arjun R¹,Mahalingeshwara Bhat K P², Sara C¹**

¹PG student in General Medicine, KS Hegde Medical Academy, Nitte University, Mangalore- 575018 (India)

²Assistant Professor of Medicine, KS Hegde Medical Academy, Nitte University, Mangalore- 575018 (India)

Corresponding author*

Abstract

Background: Steven Johnsons syndrome is an acute, life threatening mucocutaneous reaction predominantly characterised by extensive necrosis and epidermal detachment.Both Steven Johnson syndrome (SJS) and Toxic Epidermal Necrolysis (TEN) are now thought to be severity variants of a single disease entity. The term *SJS* pertains to cases with blisters developing on target lesions, dusky or purpuric macules with significant mucosal involvement, and total body surface area blistering and eventual detachment is inevitable in as much as <10% of cases. Risk of mortality in SJS has been purported to be less than 10%. In about 60% of cases, an association with a medication can be clearly established.

Methodology: This study was conducted by using data of patients diagnosed with Steven Johnson syndrome in a university teaching hospital from January 2012 to August 2016. History, clinical and laboratory data were obtained and summarized.

Results: Twenty-one patients were diagnosed with Steven Johnson syndrome during the study period. Nine patients (42.8%) were males and twelve patients (57.2%) were females. Mean age of study population was 37.9 years. Phenytoin was identified as the most common drug etiology. In about five patients (23.8%) the causative drug could not be identified. One patient succumbed due to severe disease.

Conclusion: The frequency of Steven Johnson syndrome is significant in our setup, thereby highlighting the importance of increasing awareness of the entity. Phenytoin was the most common drug identified in the etiology of Steven Johnson syndrome in our study. In a patient diagnosed with Steven Johnson syndrome in response to drug exposure, it is always imperative to avoid re-exposure of the drug.

Keywords- Steven Johnson syndrome, Drug induced.

Introduction

Steven Johnson syndrome (SJS) and Toxic Epidermal Necrolysis (TEN) are severe mucocutaneous reactions, most commonly attributable to various drugs, characterized by blistering and sloughing of epithelium.¹ These two terms describe phenotypes within a varying severity spectrum, in which SJS is the less extensive and TEN, the more extensive entity. The incidence of SJS/TEN has been

postulated to be approximately 1– 2 cases per million per year. Although rare, SJS/TEN is a devastating disease; in severe cases the acute phase may be complemented by a variety of systemic complications, including multiorgan failure. The mortality for SJS has been purported to be less than 10%, with the figure rising to 30% in cases concerning TEN; overall SJS/TEN mortality is about 22%. As well as carrying an appreciable degree of mortality,

survivors of the acute illness are often noted to develop significant long-term sequelae.²

Materials and Methods

Study was conducted by utilizing data of patients diagnosed with Steven Johnson syndrome in a university teaching hospital from January 2012 to August 2016. History, clinical and laboratory data were obtained and summarized.

Results

Twenty one patients were diagnosed with

Steven Johnson syndrome during the study period. Nine patients (42.8%) were males and twelve patients(57.2%) were females. Mean age of study populace was 37.9 years. Phenytoin was the most common drug etiology identified. In about five patients (23.8%) the causative drug could not be identified. One patient succumbed due to severity of disease. The age distribution of cases and drug etiology are as described in figure 2 and figure 3 respectively.

Gender Distribution

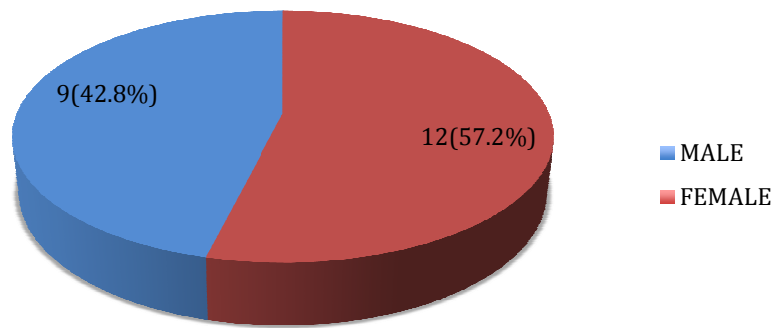


Figure 1 – Gender distribution of study population

AGE DISTRIBUTION

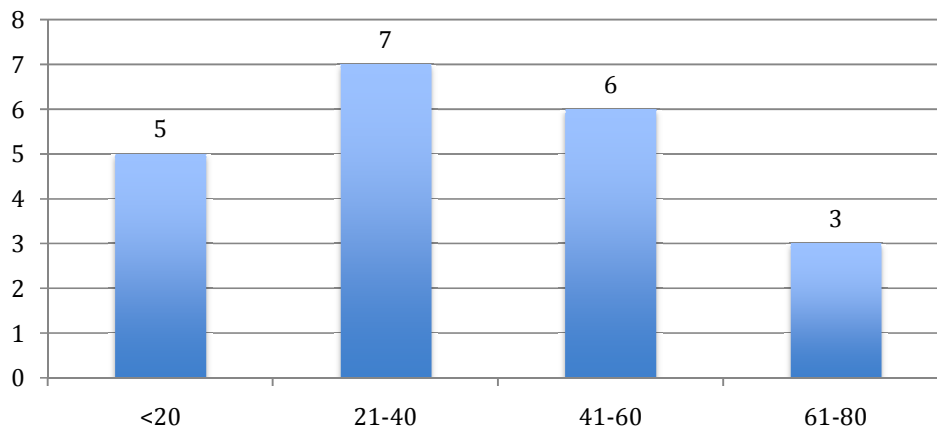


Figure 2 – Age distribution of study population

CAUSATIVE DRUG

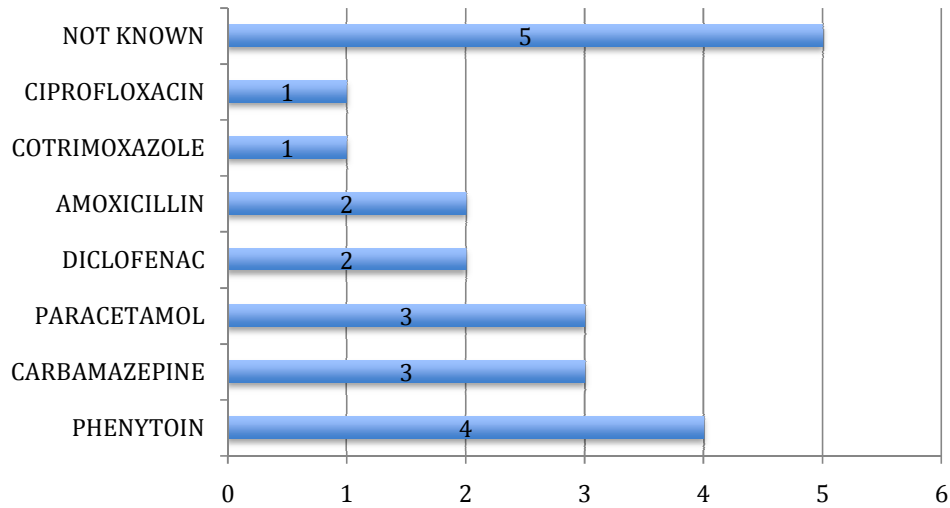


Figure 3 – Drug etiology

DISCUSSION

Initial symptoms of toxic epidermal necrolysis (TEN) and Stevens Johnson Syndrome (SJS) may be vague and include a spectrum of symptoms such as fever, stinging eyes and discomfort upon swallowing. Characteristically, these symptoms precede cutaneous exhibitions by a few days. Early sites of cutaneous involvement mainly include the pre-sternal regions of the trunk and the facial region, as well as the palms and soles. Involvement (erythema and erosions) of the buccal, genital and/or ocular mucosa tends to occur in more than 90% of patients, and in some instances, the respiratory and gastrointestinal tracts are also involved.^{3,4} Ocular involvement at the onset of disease has been noted to be a frequent finding, and these may vary from acute conjunctivitis, edema of eyelids, erythema, crusting, and ocular discharge to conjunctival membrane or pseudo-membrane formation and corneal erosion. In severe cases, cicatrizing lesions,

symblepharon, fornix foreshortening, and corneal ulceration are the discerning features.⁵

During the second phase of illness, large areas of epidermal detachment tend to develop. In the absence of this impending detachment of epidermis, more detailed skin examination must be performed by exerting tangential mechanical pressure on several affected erythematous zones (Nikolsky sign). The Nikolsky sign is considered positive if mechanical pressure successfully induces epidermal detachment. It is imperative to note that this is not specific for TEN or SJS, as it can also be positive in various other entities such as autoimmune bullous skin diseases.⁴ The extent of dermal involvement is a major prognosticating factor. It is important to note that only necrotic skin, which is already detached (such as blisters or erosions) or detachable skin (Nikolsky positive) should be included in the evaluation for extent of skin involvement. Histological analysis, including direct immunofluorescence analysis of the skin

biopsy is also important in order to rule out various possible differential diagnoses such as autoimmune blistering diseases, bullous fixed drug eruptions, acute generalized exanthematouspustulosis, and due to its paucity in the adult populace, to a lower extent,

staphylococcal scalded skin syndrome as well (Table 1).⁶

Previously, Bastuji-Garin et al. proposed classifying patients into three groups based on the degree of skin detachment (Figure 4)⁷

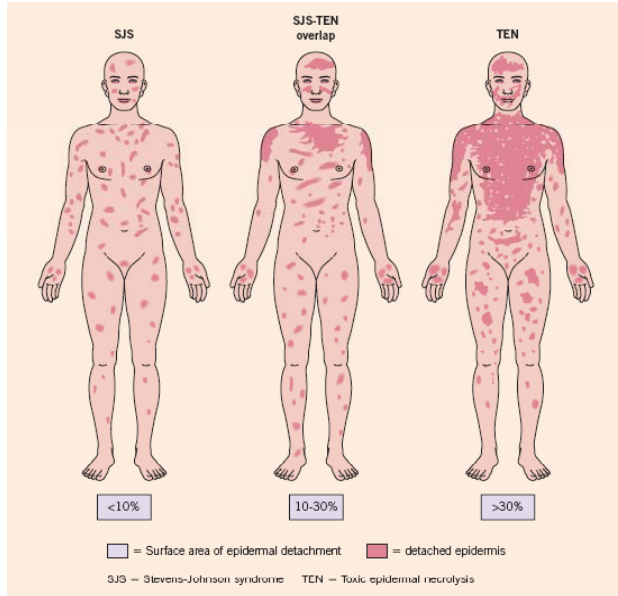


Figure- 4Pictorial representation of SJS, SJS-TEN overlap and TEN showin the surface of epidermal attachment⁷

Table 1 DIFFERENTIAL DIAGNOSIS OF SJS
Pemphigus vulgaris
Mucous membrane pemphigoid
Bullous pemphigoid
Paraneoplastic pemphigus
Erythema multiforme major
Generalized bullous fixed drug eruption
Bullous acute graft-versus-host disease
Staphylococcal scalded skin syndrome
Acute generalized exanthematouspustulosis

Management and Therapy

Treatment during the Acute Phase-

Management in the acute stage is a sequential process and involves evaluation of the severity and prognosis of disease, prompt identification and withdrawal of the purported culprit drug(s), rapidly initiating supportive care in an appropriate setting, and eventual “specific” drug therapy.

Rapid evaluation of severity and prognosis-

Once the diagnosis of SJS or TEN has been relatively clearly established, the severity and prognosis of the disease must be identified, so as to define the appropriate medical setting for further management. In order to evaluate prognosis in patients with SJS/TEN, the validated SCORTEN disease severity scoring system can be used (Table - 2) ⁶

SCORTEN Parameter	Individual score	SCORTEN (sum of individual scores)	Predicted mortality (%)
Age > 40 years	Yes = 1, No = 0	0-1	3.2
Malignancy	Yes = 1, No = 0	2	12.1
Tachycardia (>120/min)	Yes = 1, No = 0	3	35.8
Initial surface of epidermal detachment >10%	Yes = 1, No = 0	4	58.3
Serum urea >10 mmol/l	Yes = 1, No = 0	>5	90
Serum glucose >14 mmol/l	Yes = 1, No = 0		
Bicarbonate >20 mmol/l	Yes = 1, No = 0		

Table – 2 SCORTEN SEVERITY SCORING SYSTEM

Prompt withdrawal of culprit drug(s)-

Prompt withdrawal of the attributed drug(s) should be a priority when blisters or erosions appear during the course of a drug eruption. Previously, Garcia-Doval et al. have shown that early withdrawal of the causative drug is associated with a greater chance of a positive prognosis. Also, the patients exposed to certain causative medications with long half-lives have an increased risk of mortality. In order that the culprit drug(s) is identified early, it is important to consider the chronology of administration of the drug and the reported capacity of the drug to induce SJS/TEN. The chronology of administration of a culprit drug, or time interval between first administration and development of SJS/TEN, has been estimated to be between 1 and 4 weeks in the large majority of cases. ⁸

Supportive Care-

A most critical element of supportive care is the management of fluid and electrolyte requirements and its balance. It is imperative that Intravenous fluids be administered. This is done in order that a urine output of 50 - 80 mL per hour is maintained.

The desired fluid is generally 0.5% NaCl, supplemented with 20 mEq of KCl. Appropriate early and aggressive replacement therapy may be important in cases of hyponatraemia, hypokalaemia or hypophosphataemia which quite frequently do occur. Wounds may be managed conservatively, without dermal debridement. This is most often performed in the burn units. Blistered skin acts as a natural biological dressing, and this most likely favors re-epithelialization. Non-adhesive wound dressings are preferred where required, and

topical sulfa containing medications should be avoided.⁶

Drug Therapy

To date, a specific therapy for SJS/TEN that has shown efficacy in controlled clinical trials unfortunately is non-existent.⁹ Several treatment modalities given in addition to supportive care have been reported in the literature.

Systemic steroids were the gold standard of treatment until the early 1990's, although no benefit has been shown in various controlled trials. In the absence of strong evidence of their efficacy, and due to the possible confusion resulting from the numerous steroid treatment regimens that have been reportedly tried, (treatment of short versus long duration, regimens utilizing different doses), their use has become increasingly disputed. A recent retrospective single center study suggests that a short course "pulse" therapy, involving use of high dose corticosteroids (dexamethasone) may be of possible benefit.⁹ On the other hand, a recent retrospective case-control study conducted by Schneck et al. in France and Germany concluded that corticosteroids did not show a significant effect on mortality in comparison with primary supportive care only.¹⁰

Thalidomide, a medication with known anti-TNF α activity also has immunomodulatory and anti-angiogenic properties and it has been evaluated for the treatment of TEN. Unfortunately, in a double-blinded, randomized, placebo-controlled evaluation, higher mortality was noted in the thalidomide-treated group suggesting that thalidomide may actually prove to be detrimental in the management of TEN.¹¹

The utility of High-dose intravenous

immunoglobulins have also been postulated and thereafter, studied. As a consequence of the discovery of the anti-Fas potential of pooled human intravenous immunoglobulins (IVIG) in vitro, IVIG have been tried for the treatment of TEN, and their effect has been reported in various different non-controlled evaluations. Taken together,⁹ out of 12 such studies suggest that there may be a possible value in utilization of high-dose IVIG, especially pertaining to the possible effects on the mortality associated with TEN. Analysis of studies published suggests that cumulative IVIG doses of more than 2 g/kg may be of greater benefit than doses of 2 g/Kg or less. Considering the more favorable side-effect profile of IVIG and the data available to date, in these authors' opinion, early administration of high-dose immunoglobulin (3 g/kg total dose given over 3-4 days) can be considered alongside supportive care for the treatment of toxic epidermal necrolysis, given the absence of other validated specific therapeutic alternatives. The concomitant administration of corticosteroids or immunosuppressive agents remains controversial.¹⁰

Ciclosporin (CsA), a calcineurin-inhibitor has been thought to be an efficient drug in transplantation and autoimmune diseases. Arevalo et al. have previously performed a study as a case series with two treatment arms: utilization of CsA alone versus cyclophosphamide in combination with corticosteroids. Patients treated with CsA were found to have significantly shorter time period to complete re-epithelialization, and fewer patients with multi-organ failure and death were observed.¹² Recently, Valeyrie-Allanore et al. conducted an open, phase II trial to determine the safety and possible benefit of

use of ciclosporin. Twenty-nine patients were included in this trial (10 SJS, 12 SJS-TEN overlap and 7 TEN). The study detailed 26 patients as having completed the treatment, with CsA administered orally (3 mg/kg/d for 10 days) and tapered over a period of one month. The prognostic score predicted 2.75 deaths. However, none occurred ($p = 0.1$), implying that, although not statistically significant, ciclosporin may yet be a useful alternative for the treatment of TEN.¹³

TNF antagonists-A new path breaking therapeutic approach targeting the pro-inflammatory cytokine TNF α has also been proposed by Hunger et al. They treated one patient with a single dose of the chimeric anti-TNF α antibody (infliximab 5 mg/kg) and reported that disease progression regressed within a time period of 24 hours followed by a complete re-epithelialization within a period of five days. However, the published data is currently insufficient to draw any certain conclusions on the therapeutic potential of TNF antagonists in TEN.¹⁴

Plasmapheresis/plasma exchange (PE)- PE has also been attempted in SJS/TEN, but the current data does not allow for any definite conclusion to be drawn as to the possible therapeutic potential of this approach, due to the small sample populace of treated patients. The frequent confounding factors in this

scenario include different or combined treatments, and other potential biases. Cyclophosphamide (CPP) has also been studied in several small case series, either in combination with other treatments such as CsA, in conjunction with high-dose corticosteroids, or as a lone medication. Although the authors of these small trials do suggest a beneficial role of CPP, larger studies are definitely warranted to clarify these preliminary results, with special emphasis needed on any potential adverse effects and outcomes.⁶

Prognosis

SJS is a severe and life threatening condition. The average reported mortality rate of SJS is 5-10% and it can be even be higher in the elderly populace as well as those with a large surface area of epidermal detachment involved.¹⁵

Conclusion

The frequency of Steven Johnson syndrome is significant in our setup, thereby highlighting the obvious importance of increasing awareness about the entity. Phenytoin was the most common drug identified in the etiology of Steven Johnson syndrome in our study. In a patient with diagnosed Steven Johnson syndrome in response to a drug, it is always important to avoid re-exposure of the attributed drug.

References:

1. Roujeau JC, Stern RS. Severe adverse cutaneous reactions to drugs. *New England Journal of Medicine*. 1994 Nov 10;331(19):1272-85.
2. Creamer D, Walsh S, Dziejewski P, Exton L, Lee H, Dart J et al. U.K. Guidelines for the management of Stevens-Johnson syndrome/toxic epidermal necrolysis in adults 2016. *Br J Dermatol*. 2016;174(6): 1194-1227.
3. Lebagry F, Wolkenstein P, Gisselbrecht M, Lange F, Fleury-Feith J, Delclaux C, Roupie E, Revuz J, Roujeau JC. Pulmonary complications in toxic epidermal necrolysis: a prospective clinical study. *Intensive care medicine*. 1997 Dec 1;23(12):1237-44.

- 4.Revuz J, Penso D, Roujeau JC, Guillaume JC, Payne CR, Wechsler J, Touraine R. Toxic epidermal necrolysis: clinical findings and prognosis factors in 87 patients. *Archives of dermatology*. 1987 Sep 1;123(9):1160-5.
- 5.Sotozono C, Ueta M, Koizumi N, Inatomi T, Shirakata Y, Ikezawa Z, Hashimoto K, Kinoshita S. Diagnosis and treatment of Stevens-Johnson syndrome and toxic epidermal necrolysis with ocular complications. *Ophthalmology*. 2009 Apr 30;116(4):685-90.
- 6.Harr T, French LE. Toxic epidermal necrolysis and Stevens-Johnson syndrome.Orphanet journal of rare diseases. 2010 Dec 16;5(1):1.
- 7.Bastuji-Garin S, Rzany B, Stern RS, Shear NH, Naldi L, Roujeau JC. Clinical classification of cases of toxic epidermal necrolysis, Stevens-Johnson syndrome, and erythema multiforme.*Archives of dermatology*. 1993 Jan 1;129(1):92-6.
- 8.Garcia-Doval I, LeCleach L, Bocquet H, Otero XL, Roujeau JC. Toxic epidermal necrolysis and Stevens-Johnson syndrome: does early withdrawal of causative drugs decrease the risk of death?.*Archives of Dermatology*. 2000 Mar 1;136(3):323-7.
- 9.Kardaun SH, Jonkman MF. Dexamethasone pulse therapy for Stevens-Johnson syndrome/toxic epidermal necrolysis.*Actadermato-venereologica*. 2007 Mar 15;87(2):144-8.
- 10.Schneck J, Fagot JP, Sekula P, Sassolas B, Roujeau JC, Mockenhaupt M. Effects of treatments on the mortality of Stevens-Johnson syndrome and toxic epidermal necrolysis: a retrospective study on patients included in the prospective EuroSCAR Study. *Journal of the American Academy of Dermatology*. 2008 Jan 31;58(1):33-40.
- 11.Wolkenstein P, Latarjet J, Roujeau JC, Duguet C, Boudeau S, Vaillant L, Maignan M, Schuhmacher MH, Milpied B, Pilorget A, Bocquet H. Randomised comparison of thalidomide versus placebo in toxic epidermal necrolysis. *The Lancet*. 1998 Nov 14;352(9140):1586-9.
- 12.Arévalo JM, Lorente JA, González-Herrada C, Jiménez-Reyes J. Treatment of toxic epidermal necrolysis with cyclosporin A. *Journal of Trauma and Acute Care Surgery*. 2000 Mar 1;48(3):473-8.
- 13.Valeyrie-Allanore L, Wolkenstein P, Brochard L, Ortonne N, Maitre B, Revuz J, Bagot M, Roujeau JC. Open trial of ciclosporin treatment for Stevens-Johnson syndrome and toxic epidermal necrolysis. *British Journal of Dermatology*. 2010 Oct 1;163(4):847-53.
- 14.Hunger RE, Hunziker T, Buettiker U, Braathen LR, Yawalkar N. Rapid resolution of toxic epidermal necrolysis with anti-TNF- α treatment. *Journal of allergy and clinical immunology*. 2005 Oct 1;116(4):923-4.
- 15.Roujeau JC, Stern RS. Severe adverse cutaneous reactions to drugs.*New England Journal of Medicine*. 1994 Nov 10;331(19):1272-85.